



**WFSLMS**

2004.5.6

# **NEWSLETTER No.7**

World Federation of Societies for Laser Medicine and Surgery

---

## **CONTENTS**

**Message from President Atsumi**

**Technical Report from Japan**

## **Message from President Atsumi**

**On assuming the presidency of the non profit organization,  
World Federation of Societies for Laser Surgery and Medicine**

As we all well know, the idea for the non-profit organization, the World Federation of Societies for Laser Surgery and Medicine originated at the 14<sup>th</sup> ISLSM(Laser Tokyo'81) which presided as the International confederation for Laser in Medicine and Surgery for which a bylaws were made. However at this time this confederation was not realized.

Later in 1996, at the 4<sup>th</sup> WALT meeting in Greece this idea was proposed and accepted and in 2001 at Chennai, India a Steering Committee was assembled, which developed into an Organizing Committee at Munich, Germany in 2003.

Since 2002 from the Pattaya, Thailand meeting a Newsletter Committee was formed and has ever since reported on new developments of WFSLMS including background and ideas of this federation.

As of February 3, 2004 the WFSLMS Fund has gained official status as a NPO and I have been appointed president of this fund, I would like to point out 2 points for discussion.

1. The difference between ISLSM and WFSLMS

**The biggest of our concerns is an how to differentiate the activities of ISLSM & WFSLMS.**

ISLSM is a purely scientific meeting for presentation of basic sciences and clinical researches done by individuals. It is held every two years, and it is only at this time that the society is in action while any other activities between meetings are solely on individual basis of members.

On the other hand, the Federation acts as a distributor of the fruits of scientific research presented at the ISLSM meetings. The dissemination of new ideas distribution of new technology is an on going activity and thereby the meeting held every 4 years is a forum to report on the activities conducted by respective Laser societies and association by their representatives. Of course, the activity of the Federation continues after the end of the meeting.

Simply stated, ISLSM is the developer while the WFSLMS is the distributor. Dissemination of worthwhile research results throughout the world is an important engagement for those involved in the medical field. WFSLMS will continue to work to reach such goals.

	The Federation WFSLMS	ISLSM
• Purpose :	distribution and discussion of research results	presentation of research results
• Period of activity :	continuous	during the meeting
• Key of activity :	activities of respective laser societies and association along with that of the Federation	private individual research

I hope that all will understand the difference between the two correctly and that all will engage in activities of both the Federation and Society.

## 2. On the NPO WFSLMS Fund

Originally, the organization started as the Kaplam-Atsumi fund, but has now changed to the NPO WFSLMS Fund. However if the WFSLMS is to engage in the action plans mentioned above it would be better if it were called NPO WFSLMS. By doing so it would clarify the relationship between WFSLMS & NPO WFSLMS.

## **Technical Report from Japan**

We send new engineering news from Japan, please read by all means.

Please give your paper if you have subject in engineering field.

### **Photo acoustic Diagnoses**

Shunichi Sato, Minoru Obara

National Defense Medical College

In recent years, optical diagnoses and imaging have been extensively investigated for medical applications. However, biological tissues are highly scattering media, and the observation depth and resolution are therefore often limited. Photoacoustic diagnosis is not a pure optical modality; we use light but what we detect is an acoustic signal, not an optical signal.

Figure 1 shows the principle of photoacoustic diagnosis. If there is a lesion in tissue and it shows specific optical absorption characteristics, acoustic wave (photoacoustic signal) can be induced in the lesion by irradiating the tissue with light that can be selectively absorbed by the lesion. By detecting the photoacoustic signal, we can obtain the information of the lesion. For example, some types of cancers involve efficient development of neovascularities, and they can therefore be sensitively detected by irradiating the tissue with green light that can be well absorbed by the blood. Photoacoustic diagnoses have both natures of optical and acoustic diagnoses, i.e., deeper observation depth can be obtained than with pure optical technique and higher resolution can be obtained than with conventional acoustic diagnoses (Figure 2). Its unique features have received much attention for medical diagnoses in various fields such as oncology, ophthalmology, plastic surgery, etc.

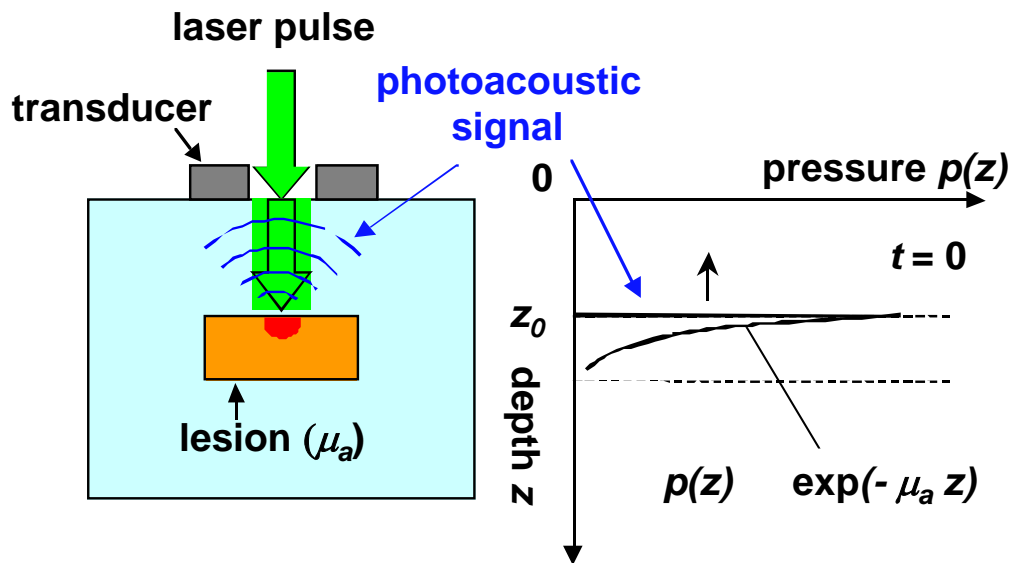


Figure 1 Principle of photoacoustic diagnosis.

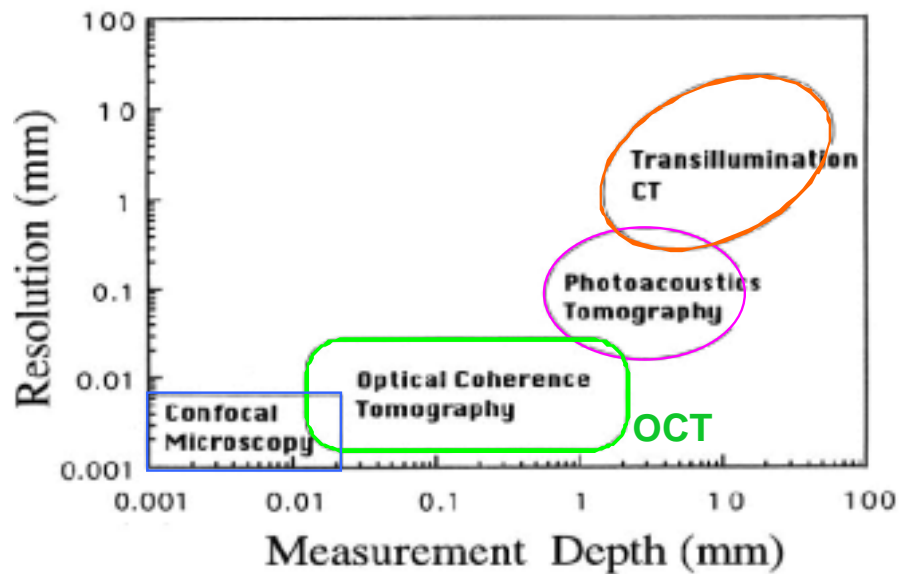


Figure 2 Resolution vs measurement depth.

Recent interesting applications of photoacoustic technique include diagnosis of burn injuries. A joint group of National Defense Medical College and Keio University has been engaged in the development of photoacoustic burn diagnosis. The idea is based on the fact that *zone of stasis* is formed in the damaged tissue, under which there is an abundant blood perfusion. It is, therefore, considered that by measuring the propagation time of the photoacoustic signal originated from the blood, depth of injury

can be assessed. Figure 3 shows distributions of photoacoustic signals (photoacoustic tomograms) for the partial thickness burn (deep dermal burn, DDB) and the full thickness burn (deep burn, DB) in rats; red regions indicate intense blood-originated photoacoustic signal. It is shown that for DDB, an intense signal layer appears at depths of 0.5 - 0.7 mm while for DB, there is no strong signal in the depth range of < 1.3 mm, indicating that burn depths are estimated to be ~ 0.5 mm for DDB and > 1.3 mm for DB. This is just animal study, but clinical application is now under investigation.

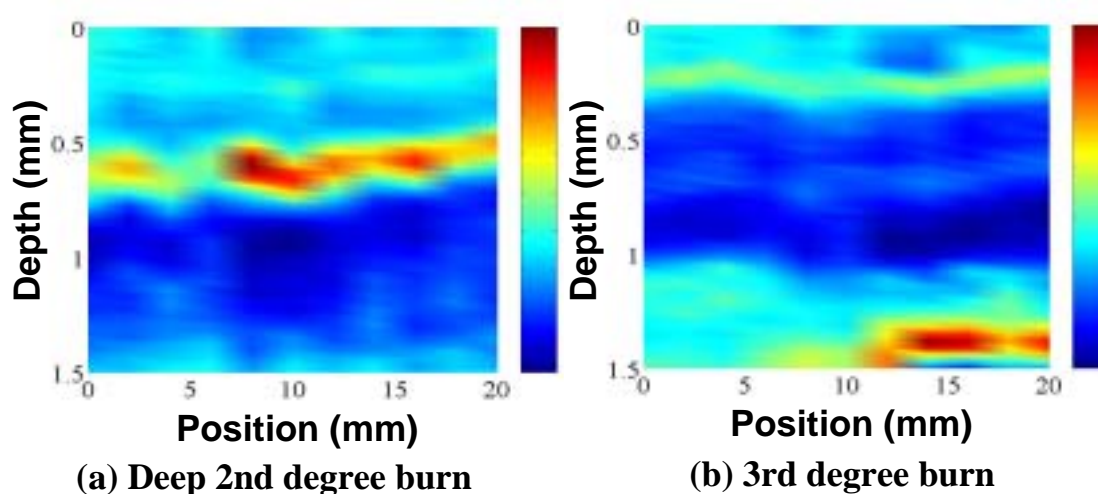


Figure 3 Photoacoustic tomograms of burns in rats.